

Chronic Paroxysmal Hemicrania-Tic Syndrome Due to Basilar Artery Dolicho-Ectasia: Case Report

Baziller Arter Dolikoektazisine Bağlı Kronik Paroksizmal Hemikrania-Tik Sendromu

Sevda ERER ÖZBEK,^a
Mehmet ZARİFOĞLU,^a
Necdet KARLI,^a
Ahmet BEKAR^b

Departments of
^aNeurology,
^bNeurosurgery,
Uludağ University School of Medicine,
Bursa

Geliş Tarihi/Received: 07.01.2013
Kabul Tarihi/Accepted: 27.05.2013

Yazışma Adresi/Correspondence:
Sevda ERER ÖZBEK
Uludağ University School of Medicine,
Department of Neurology, Bursa,
TÜRKİYE/TURKEY
sevdaerer@uludag.edu.tr,

ABSTRACT Chronic paroxysmal hemicranias (CPH)-tic syndrome is characterized by a CPH accompanied by trigeminal neuralgia on the same side of the face, either simultaneously or at different time-points. Although (KPH)-tic syndrome is a common type of primary headache, it may also appear as a secondary headache. We present a case of CPH-tic syndrome secondary to basilar artery dolichoectasia, in which the complaints were eliminated using microvascular decompression (MVD) surgery that was performed upon the lack of response to medical therapy. Based on our literature searches, this is the first case of KPH-tic syndrome treated with MVD surgery.

Key Words: Trigeminal neuralgia; chronic pain; basilar artery; headache disorders

ÖZET Kronik paroksizmal hemikrania (KPH)-tik sendromu, aynı yüz yarısında olan KPH ile farklı zamanlarda ya da eş zamanlı olarak, trigeminal nevrjaljinin birlikte görüldüğü klinik tablodur. (KPH)-tik sendromu, sıklıkla primer bir baş ağrısı olmakla birlikte sekonder baş ağrısı olarak da ortaya çıkabilir. Biz; baziller arter dolikoektazisine bağlı ortaya çıkan, medikal tedaviye cevap vermeyip mikrovasküler dekompresif (MVD) cerrahi girişimle yakınmaları ortadan kalkan bir KPH-tik sendromunu olgusunu sunmaktayız. Literatürde ulaşılabildiğimiz kadarıyla MVD cerrahisiyle tedavi edilen ilk KPH-tik sendromu olgusudur.

Anahtar Kelimeler: Trigeminal nevrjalji; kronik ağrı; baziler arter; baş ağrısı bozuklukları

Türkiye Klinikleri J Neur 2013;8(3):107-10

Chronic paroxysmal hemicrania (CPH) is a type of single-sided headache that is characterized by severe pain attacks that last from 2-45 minutes and occurs between 2-40 times per day. The headache occurs at supraorbital or temporal locations. CPH is generally accompanied by autonomic features such as lacrimation, ptosis and nasal congestion or discharge. CPH attacks can occur on a daily basis for years without remission. Trigeminal neuralgia is characterized by a single-sided (unilateral) spasm and pain, which has a short duration at one or more branches of the trigeminal nerve.¹⁻³

When CPH and trigeminal neuralgia occur together, it is known as CPH-tic syndrome. These two entities can occur synchronously or at different time points.^{4,5}

In this report, we present a case of CPH-tic syndrome due to the basilar artery dolicho-ectasia. Microvascular decompression (MDV) surgery that was performed upon the lack of response to medical therapy resulted in the resolution of the symptoms. To the best of our knowledge, it is the first case with these features in the literature.

CASE REPORT

A 64 year-old male patient complaining of a moderate repetitive headache localized to the left side of his face for the last five years was admitted to our hospital. He also had accompanying autonomic features that included lacrimation, redness of the eye, swelling of the eye lid and nasal discharge on the left side. Episodes of pain lasted between 20-30 minutes and recurred at least 40 times a day. Additionally, nearly four years ago,

the patient experienced severe pain 3-4 times a day on the same side of his face, which was consistent with the involvement of the ophthalmic and maxillary branches of the trigeminal nerve. Pain was triggered by touching, chewing and swallowing and occurred in flashes. His complaints did not regress despite administration of various medications including indomethacin (150 mg/d), oxcarbazepine (600 mg/d), verapamil (360 mg/d) and gabapentin (2400 mg/d). The neurological examination revealed the presence of hypoesthesia localized in the area that was innervated by the ophthalmic and maxillary branches of the trigeminal nerve. Pain was triggered by touching. Both cranial spin echo and constructive interference in steady state sequence MRI were performed and revealed that the right vertebral artery was hypoplastic and, the left vertebral artery was dilated and tortuous and in close proximity to the trigeminal nerve. The basilar artery was dolicho-ectatic and compression of the trigeminal nerve was found (Figures 1 and 2). This suggested the concurrence of CPH and trigeminal neuralgia. After a neurosurgery consultation MVD surgery was

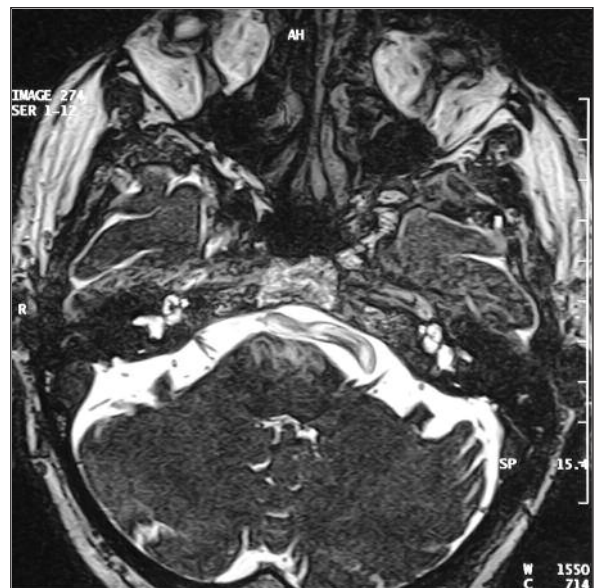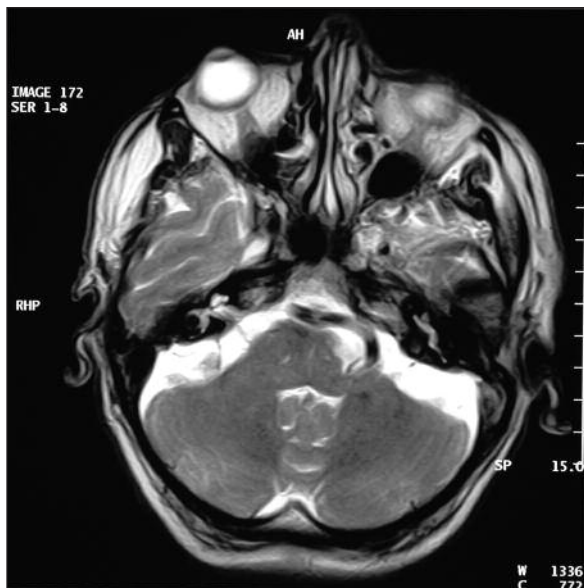


FIGURE 1-2: In the sections that pass through the skull base, it was noticed that right vertebral artery was not clearly visible and left vertebral artery (**little white arrow in the left figure**) and, then, basilar artery (**large white arrow**) were large and slightly tortuous. This enlargement is seen to compress the contiguous trigeminal nerve (**the black line shown with a white arrow in the right figure**).

performed. The patient gave his written informed consent before the surgical operation. During the MVD surgery via the retrosigmoid approach the anterior inferior cerebellar artery (AICA) and superior cerebellar artery (SCA) formed a loop and compressed the inferior aspect of the trigeminal nerve. Both the AICA and the SCA were transpositioned from the trigeminal nerve to achieve decompression. The patient has been on post-operative follow-up for nine months after surgery and has not received any medication since surgery, as he no longer suffered from headaches. His neurological symptoms were also improved.

DISCUSSION

Secondary CPH-tic syndrome is an extremely rare clinical presentation. It was first reported in the literature by Hannerz in 1993 as a case report.¹ Most reports related to paroxysmal hemicranial-tic syndrome are primary cases and there is only one case of secondary CPH-tic syndrome in the literature.⁶ Monzillo et al. published a case of CPH-tic syndrome related to a Chiari type 1 malformation.⁶ Similar to our case, a 54-year-old female patient was diagnosed with paroxysmal hemicranias; pain symptoms consistent with trigeminal neuralgia were added to her clinical presentation later. Nonetheless, the difference between that case and our case was the suggestion of syringomyelia that affected the superior cervical trigeminal nucleus related to a Chiari type 1 malformation.⁶

Various causes of secondary CPH have been described including gangliocytoma, collagenous vascular diseases, cerebrovascular diseases, Pancoast tumors, cavernous sinus meningioma, frontal lobe tumors, intracranial hypertension, aneurisms, occipital lobe infarcts, hamartomas and orbital inflammatory diseases.⁶

The relationship between the concurrence of paroxysmal hemicrania and trigeminal neuralgia is not known. It was suggested to be incidental or a comorbid condition. It was presumed that paroxysmal hemicrania initiated neuralgic pain by stimulating the trigeminal nerve peripherally.⁷

It was also considered that CPH-tic syndrome might develop due to removal of the inhibitory mechanisms that control afferent activity of the trigeminal nucleus and hypothalamic functions.⁸

Boes et al. reported a similar case of a patient who had vertebrobasilar ectasia with close proximity of the basilar artery and the trigeminal nerve along with related CPH and trigeminal neuralgia.⁹ That patient responded partially to medical treatment with verapamil 480 mg/d and topiramate 300 mg/d. However, this patient differed from our patient, because the basilar artery with ectasia was close to the entrance of trigeminal nerve and MVD surgery was not considered.

Solomon et al. reported that while patients with trigeminal neuralgia benefitted from vascular decompression surgery, patients with cluster headaches did not. They suggested that the difference between these two entities was related to the etiologies being different.¹⁰

The difference between our case and the other cases mentioned was that there was a complete improvement of the pain symptoms following MVD surgery.

In conclusion, our case is the first example in the literature of a secondary CPH-tic syndrome that improved following MVD. We aimed to highlight that surgery directed at the underlying cause could result in favorable outcomes and a higher quality of life, without the need for mono- or polytherapy in cases with CPH-tic syndrome.

REFERENCES

1. Hannerz J. Trigeminal neuralgia with chronic paroxysmal hemicrania: the CPH-tic syndrome. *Cephalalgia* 1993;13(5):361-4.
2. Caminero AB, Pareja JA, Dobato JL. Chronic paroxysmal hemicrania-tic syndrome. *Cephalalgia* 1998;18(3):159-61; discussion 124.
3. Headache Classification Subcommittee of the International Headache Society. The International Classification of Headache Disorders: 2nd ed. *Cephalalgia* 2004;24 (Suppl 1):9-160.
4. Zukerman E, Peres MF, Kaup AO, Monzillo PH, Costa AR. Chronic paroxysmal hemicrania-tic syndrome. *Neurology* 2000;54(7):1524-6.
5. Martínez-Salio A, Porta-Etessam J, Pérez-Martínez D, Balseiro J, Gutiérrez-Rivas E. Case reports: chronic paroxysmal hemicrania-tic syndrome. *Headache* 2000;40(8):682-5.
6. Monzillo P, Nemoto P, Costa A, Rocha AJ. Paroxysmal hemicrania-tic and Chiari I malformation: an unusual association. *Cephalalgia* 2007;27(12):1408-12.
7. Goadsby PJ, Lipton RB. Paroxysmal hemicrania-tic syndrome. *Headache* 2001;41(6):608-9.
8. Sanahuja J, Vazquez P, Falguera M. Paroxysmal hemicrania-tic syndrome responsive to acetazolamide. *Cephalalgia* 2005;25(7):547-9.
9. Boes CJ, Matharu MS, Goadsby PJ. The paroxysmal hemicrania-tic syndrome. *Cephalalgia* 2003;23(1):24-8.
10. Solomon S, Apfelbaum RI, Guglielmo KM. The cluster-tic syndrome and its surgical therapy. *Cephalalgia* 1985;5(2):83-9.